



Our humble roots: Dentures

APRIL 20,2015



Dr. Morley S. Rubinoff,
Prosthodontist
Implant Dentistry

**Suite 100, 2001 Sheppard
Avenue East
Toronto, Ontario, M2J 4Z7**

**Office: 416 499-1704
Cell: 416 838-1622
Fax: 416 751-1045**

Email:
drmorleyrubinoff@bell.net
drmorleyrubinoff@gmail.com

Fellow: International Team for
Implantology (Canada) Sec-



RUBINOFF PROSTHODONTICS

For some of you, it has been a long time since you made a complete denture. Dentures fly all over the mouth and often end up in someone's soup. Ergo, implants!

What happens when our patient cannot afford implants? What if the remaining alveolar ridge is atrophic and therefore has limited retentive capabilities?

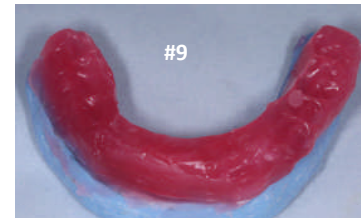
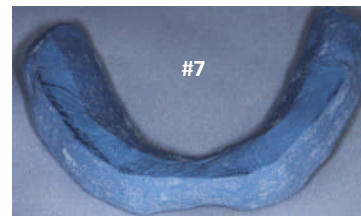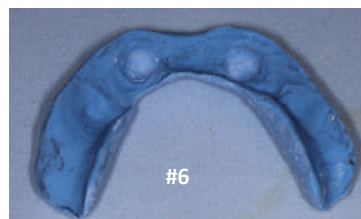
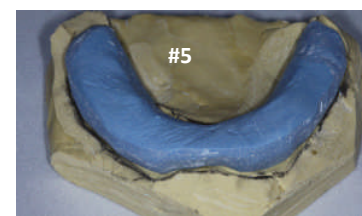
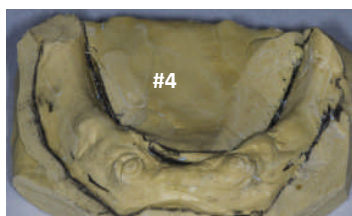
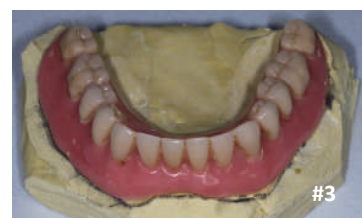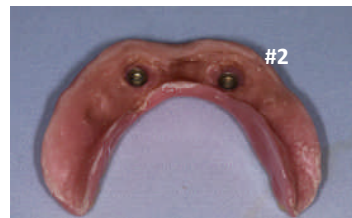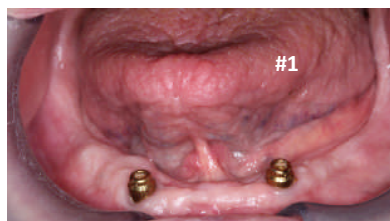The solution may be a kind referral to your friendly neighborhood Prosthodontist or Denturist colleague. Alternatively, you may wish to utilize the "Physiologic Impression Technique" that is outlined in this blog.

CASE ONE:

- ◆ Our patient has an atrophic mandibular ridge.
- ◆ Our patient has recently had two dental implants placed in the canine region #43,33 sites

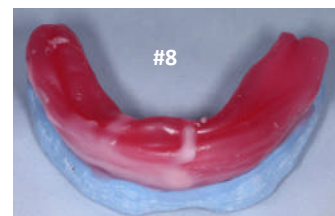
Our goal in treatment:

- Full coverage of lower arch "NO BIKINI DENTURE"!!!
- Stable lower denture base that will not easily fracture
- Additional denture stability and retention from two locators placed in #43,33 sites.



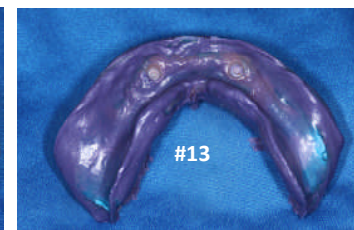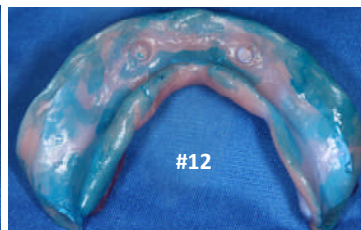
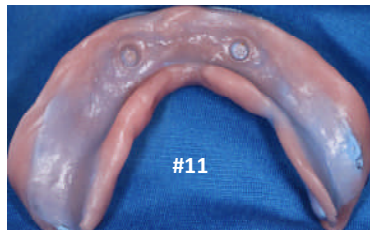
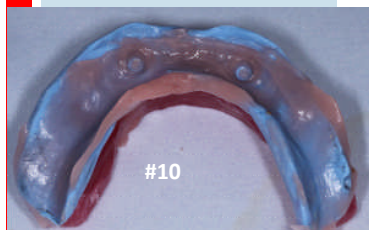
Custom Tray Fabrication:

- #6 Inside of custom tray
- #7 Flattened outside of custom tray
- #8 Occlusal rim with warm wax
- #9 Bite registration against UCD



Impression with Coe Soft\Impregum

- #10 Low viscosity applied in occ'n
- #11 High viscosity applied in occ'n
- #12 Apply impregum adhesive
- #13 Final impression: Impregum (Border mold with mouth open)

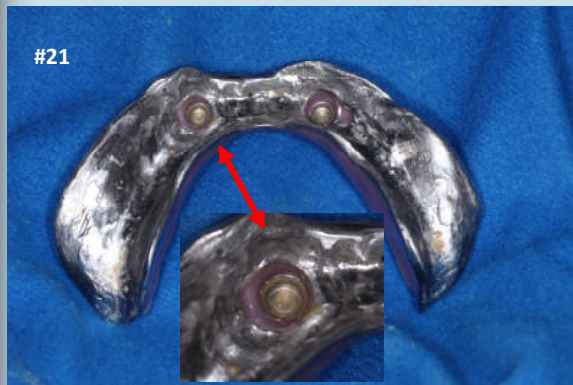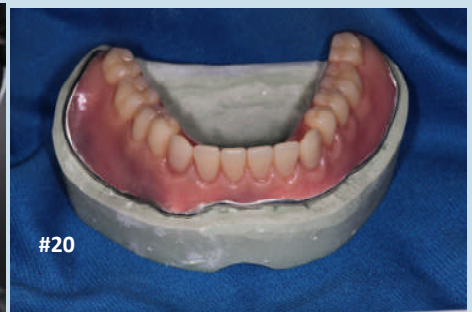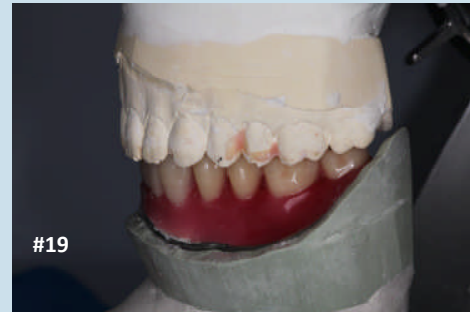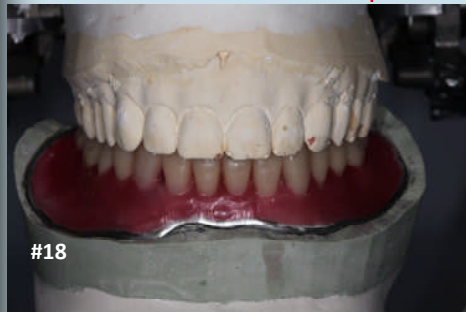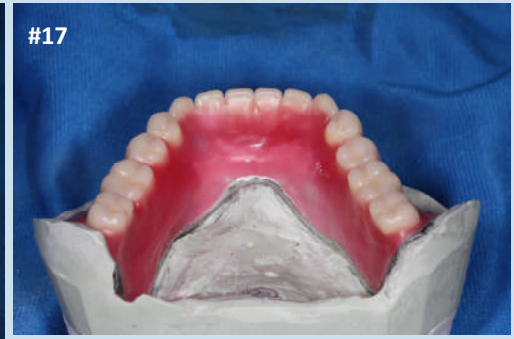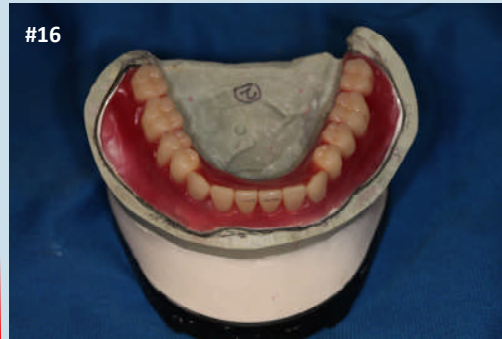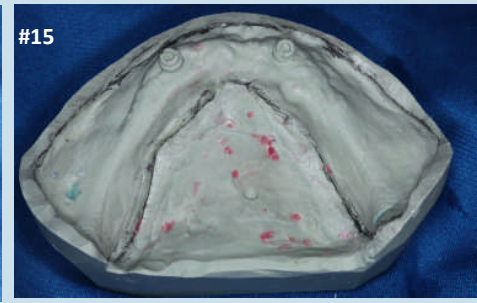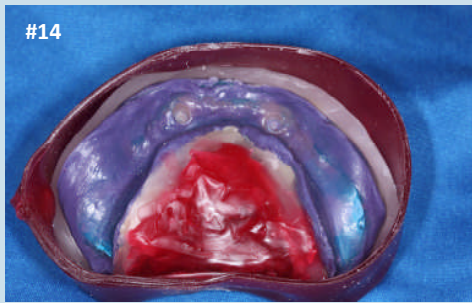


Physiologic or Functional impression technique: Utilizes incrementally more viscous applications of soft reline material followed by a final wash of elastomeric impression material. Patient occludes on wax during applications of soft reline material.

RUBINOFF PROSTHODONTICS

About my Lab Technician:

Masoud Niknejad of Picasso Dental Studios is a Master Ceramist. He maintains his own laboratory in Richmond Hill, Ontario.



POUR UP MASTER CAST, SET UP TEETH, PROCESS DENTURE BASE

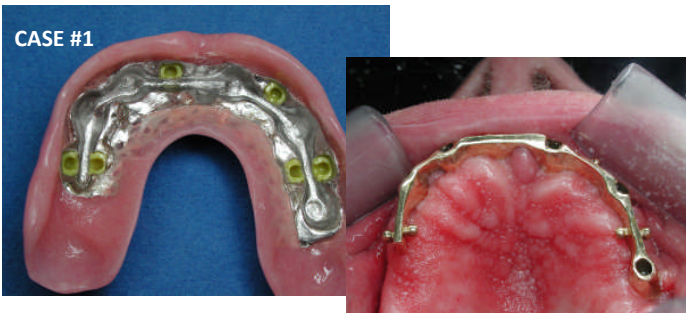
- #14 Boxing of final impression for pour up
- #15 Lower master cast poured in harder stone
- #16 Set up denture teeth (in wax) on Kavo articulator (Front view)
- #17 Set up denture teeth (lingual view)
- #18 Set up denture wax in occlusion (Frontal view)
- #19 Set up denture wax in occlusion (Lateral view)
- #20 Processed denture attached to cast chrome metal base
- #21 Locators are retrofit in the mouth and luted in place with pink repair acrylic

Chairside insertion of locators:

I prefer to attach locators to the denture base at chairside. There is often processing errors during the completion of dentures on the lab bench.

Featured in our next Blog: FIXED\DETACHABLE IMPLANT RETAINED PROSTHETICS:

CASE #1



CASE #2

