

June 28, 2015



Dr. Morley S. Rubinoff,
Prosthodontist
Implant Dentistry

Suite 100, 2001 Sheppard Avenue East
Toronto, Ontario, M2J 4Z7

Office: 416 499-1704

Cell: 416 838-1622

Fax: 416 751-1045

Email:

drmorleyrubinoff@bell.net

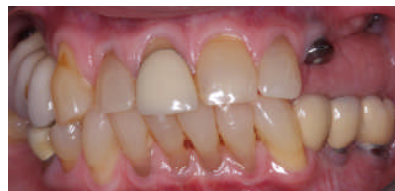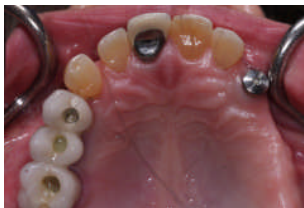drmorleyrubinoff@gmail.com

Fellow: International Team
for Implantology (Canada)



CASE TWO:

Add Bells Palsy to a Class Two Division One malocclusion with collapsed anterior teeth and missing posterior teeth..... You have a complicated dental reconstruction. Our patient wants a great smile. Can Prosthodontists do plastic surgery too?



Bimaxillary Protrusion (Restoring Class 2 Bites)

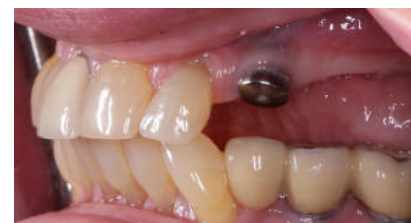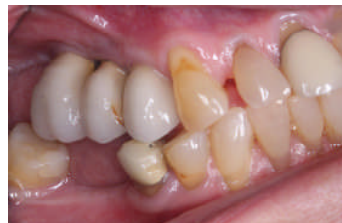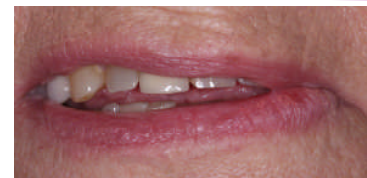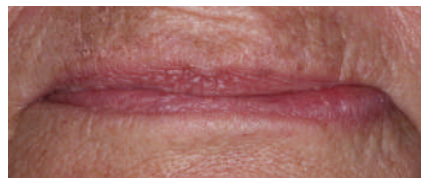


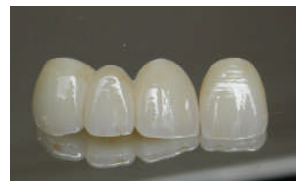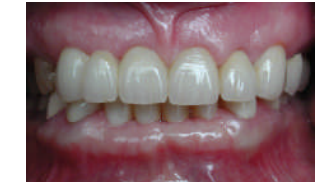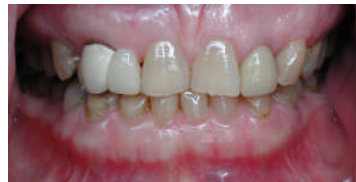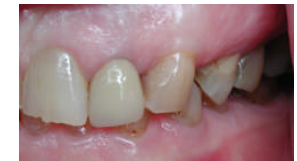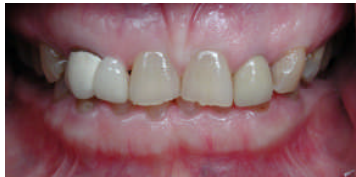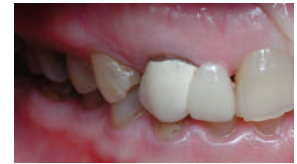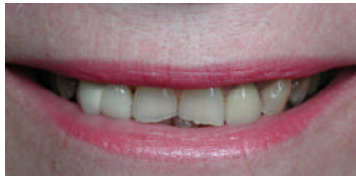Prosthodontists see lots of patients with Class Two malocclusions. Many of these patients never received orthodontic care as a youth and they now refuse Ortho care as an adult. Often, these patients have crowding or collapsed teeth into edentulous spaces. Further, many of these patients have lost vertical dimension of occlusion and exhibit anterior attrition.

CASE ONE:

Our first patient has lots of problems:

- ◆ Parafunction with wear of anterior and posterior teeth
- ◆ Class Two Division Two malocclusion
- ◆ Lost Vertical Dimension of Occlusion.
- ◆ SHE HATES HER SMILE!



All pictures here are pre treatment photos including the implant placed in the #23 site. The teeth appear to be canted low on the right and high on the left in the horizontal anterior plane. The flaccid lip will be filled out a little but the damage done to the nerve around the upper lip cannot be repaired. In this case, provisionals help to develop the aesthetics and are transferred and copied by the laboratory.



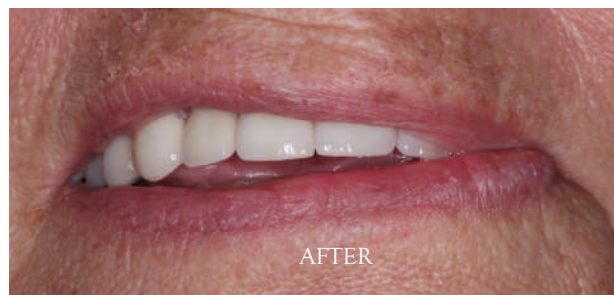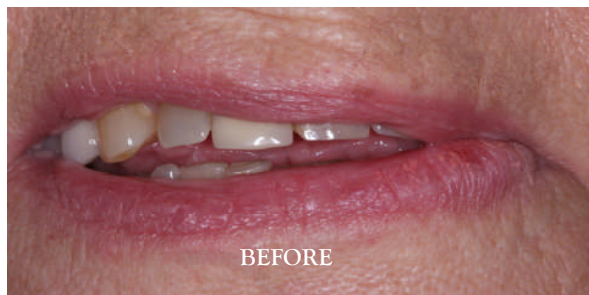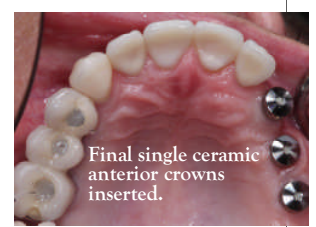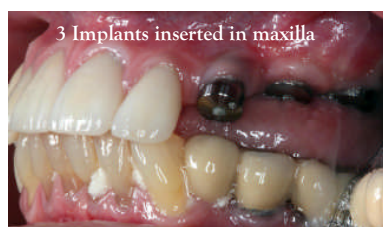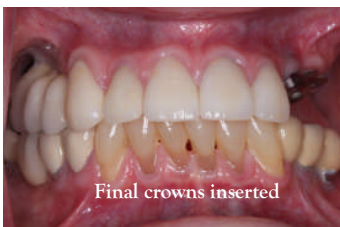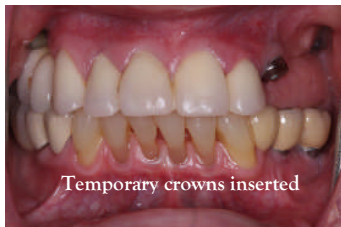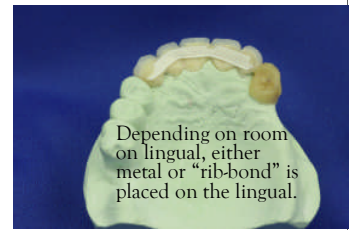
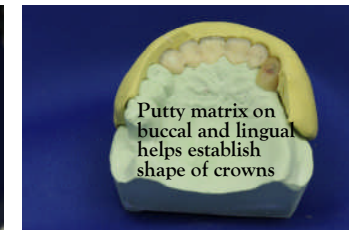
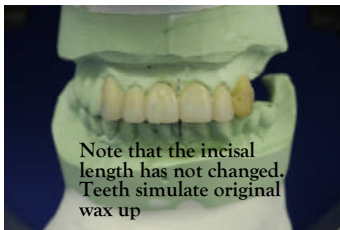
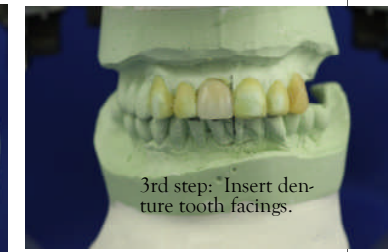
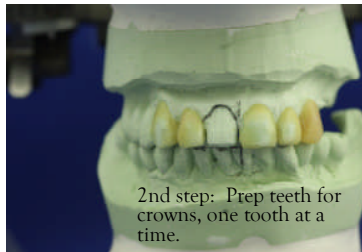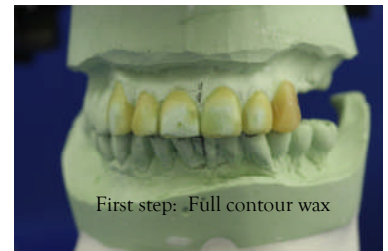

About my Lab Technician:

Masoud Niknejad of Picasso Dental Studios is a Master Ceramist. He maintains his own laboratory in Richmond Hill, Ontario.



Fabricating custom temporary crowns:

Why bother making such nice temporary crowns? They are only in the mouth a short time and then the lab can make a fabulous final prosthesis. Aesthetic concerns here are high. We need to test what can be accomplished against the upper lip in our temporary prosthesis and then guide the laboratory in the fabrication of the final prosthesis. Also, we used denture tooth facings to the aesthetics of enhance our provisional prosthesis.



Happy Patient!
Same flaccid Lip
Better Function!
How would you treat this patient?
Let me know.

