



Long term marriages in Dentistry –Part One

December 20,2016

RUBINOFF PROSTHODONTICS

Volume 2, Issue 14



Dr. Morley S. Rubinoff,
Prosthodontist
Implant Dentistry

**Suite 202, 2901 Bayview Ave.
Bayview Village Dental
Specialists
Toronto, Ontario, M2JK 1E6**

**Office: 647-347-8591
Cell: 416 838-1622
Fax: 416 224-1780**

Email:
drmorleyrubinoff@bell.net

Fellow: International Team for
Implantology (Canada) Section)



First “retreatment”

Treatment for our patient has spanned over 20 years.

Initial retreatment commenced 10 years ago and consisted of the following:

- ◆ Fabrication of a new upper complete denture with modification to shape and position of upper anterior teeth (Fig. 7, 8,9 10)
- ◆ Replacement of lower bridge (Fig. 9)

The Force of Occlusion take its toll over many years. This article reviews the care and management over time.

Meet Doris, A charming lady with a challenging occlusal scheme. Edentulous in the maxilla, partially edentulous in the mandible, she has a class two division one malocclusion. With just six remaining teeth in the lower arch, she is always pounding the upper anterior teeth (fig. 6) and placing her lower splinted teeth in heavy contact.

Over the years, our dental marriage has worked well. She will wear down her upper teeth, loose bone support around her edentulous maxilla and stress and get decay around her lower anterior teeth. It's a cycle many restorative dentists have witnessed many times.

These patients tell us that they won't leave us until we retire or they die. Gotta love em!

Take a look at Doris's lips. The lip is tense, full, foreboding..... What lies beneath? (Fig 1). Now look at her smile. Teeth worn down, Is this attrition normal? (Fig. 2) “Patch up” dentistry is visible on her lower crowns. (Fig 3) It's time for new lower crowns but are the roots healthy enough to consider new lower fixed prosthetics. The radiographs suggest considerable some lower anterior bone loss but clinically, the lower prosthesis is sound (**for now**). When you examine the lateral views, the attrition is more apparent and the strain on the lower anterior teeth is obvious. (Fig. 4,5)

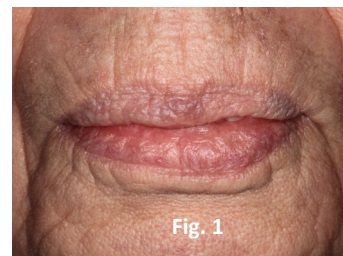


Fig. 1

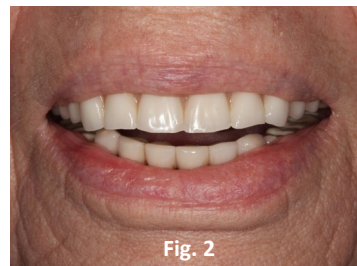


Fig. 2

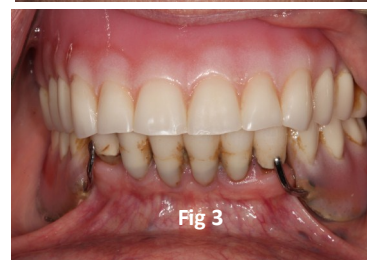

Fig 3

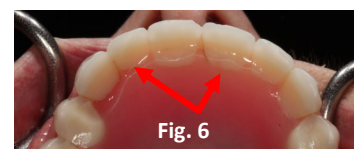

Fig. 6

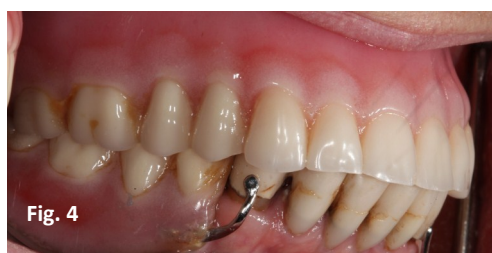

Fig. 4

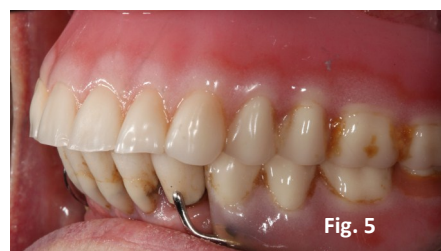

Fig. 5

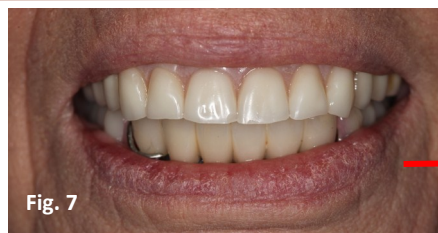

Fig. 7

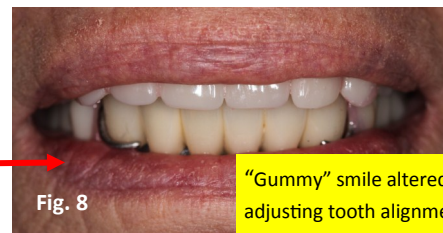

Fig. 8

“Gummy” smile altered by adjusting tooth alignment.

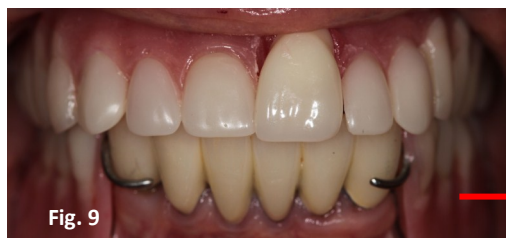

Fig. 9

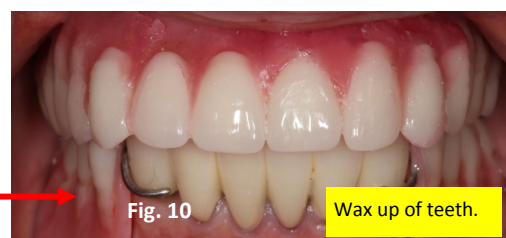

Fig. 10

Wax up of teeth.

Second "Retreatment"

It's Sunday and the phone rings. "My lower front teeth just broke off. Can you help me". Doris got seven good years out of her latest lower splinted crowns but now, her teeth are broken off at the gingival crest. (Fig. 11)

Treatment protocol:

- ◆ Lute the fractured lower anterior or bridge to the lower removable partial denture forming a temporary complete denture during the healing phase of implant surgery on #42,32
- ◆ Referral for endodontics on #42,31
- ◆ "Dome" (reshape) the natural teeth at the gingival crest, creating room for denture teeth. (Fig. 13)
- ◆ Place two bone level Straumann implants in sites #42,32 (Fig. 14,15,16,17)
- ◆ Place two locator attachments on implants #42,32
- ◆ Fabricate lower distal extension partial over-denture (Fig. 18)
- ◆ Amalgam stops in LPD\UCD re grinding habit. (Fig. 19,20)

About my Lab Technician:

Masoud Niknejad of Picasso Dental Studios is a Master Ceramist. He maintains his own laboratory in Richmond Hill, Ontario.

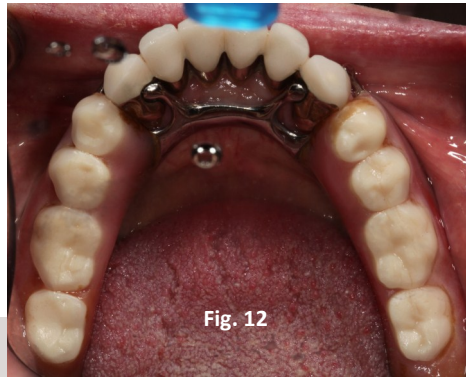


Fig. 12

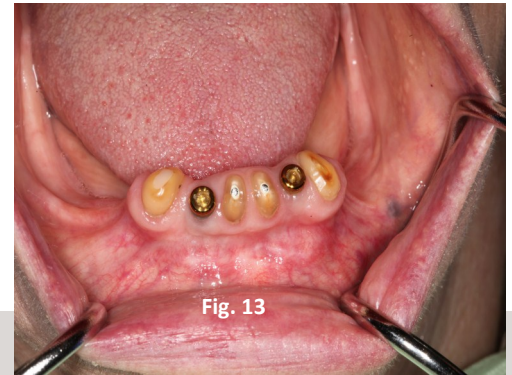

Fig. 13

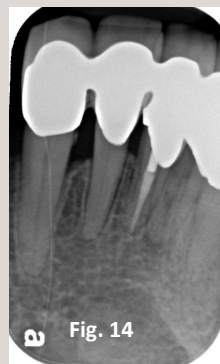


Fig. 14

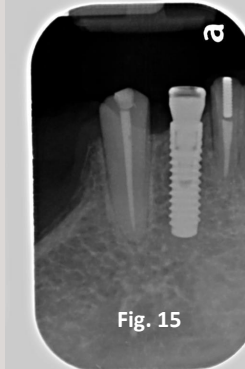


Fig. 15

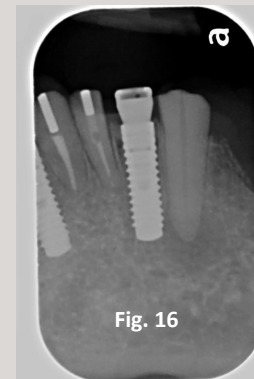


Fig. 16

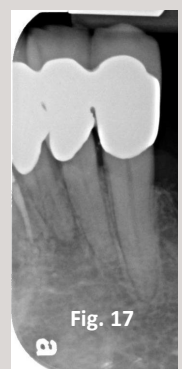

Fig. 17

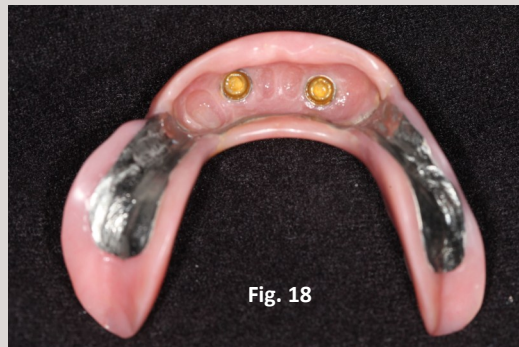

Fig. 18

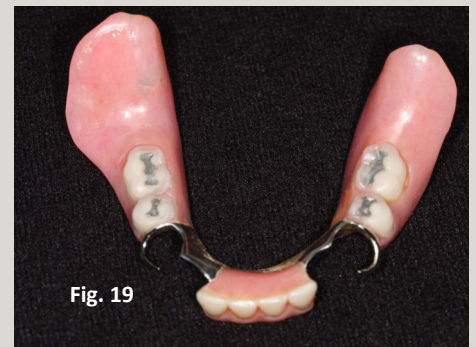

Fig. 19

Discussion:

Preservation of the anterior mandibular ridge is essential in this case. There are no undercuts on the labial or lingual alveolar crest that might rub against the walls of the denture. Retention of the new lower prosthesis depends not only on the two locators but the block of bone that will remain around the natural tooth roots. The only downside is the potential for dental caries and soft tissue inflammation around the teeth. We could have placed more implants but Doris is delighted with the fit and function of the prosthesis as is.

YOUR COMMENTS ARE ALWAYS WELCOME:

Since hindsight is always 20\20, different treatment plans could have been considered. Let me know what you think..... Dr. Rubinoff

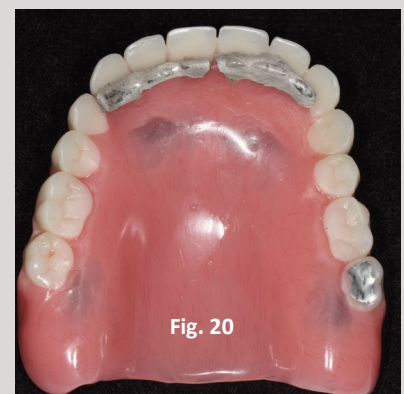

Fig. 20

Use\Abuse of Porcelain Denture Teeth:

Some prosthodontists will choose porcelain denture teeth vs acrylic denture teeth for upper anterior teeth against opposing ceramic or natural teeth. Many clinicians like myself prefer to use more resilient acrylic denture teeth which undergo attrition vs porcelain teeth that may direct forces to the underlying bony ridge.