



# Long term marriages in Dentistry –Part Two

December 28, 2016

RUBINOFF PROSTHODONTICS

Volume 2, Issue 15



**Dr. Morley S. Rubinoff,**  
Prosthodontist  
Implant Dentistry

**Suite 202, 2901 Bayview Ave.**  
**Bayview Village Dental**  
**Specialists**  
**Toronto, Ontario, M2JK 1E6**

**Office: 647-347-8591**  
**Cell: 416 838-1622**  
**Fax: 416 224-1780**

**Email:**  
drmorleyrubinoff@bell.net

**Fellow:** International Team for  
Implantology (Canada) Section



## “Retreatment” Plan:

- ◆ Extract #17,13,12
- ◆ Simultaneous implant placement in the region of #17,14,13,12 with bone augmentation as required
- ◆ Simultaneous sinus lift (indirect) in the region of #17
- ◆ Simultaneous Insertion of a temporary removable partial denture.

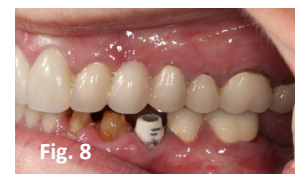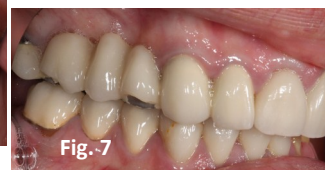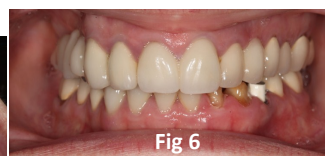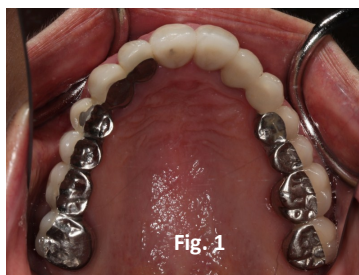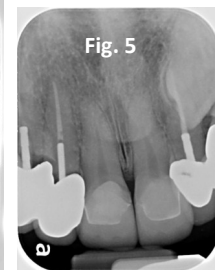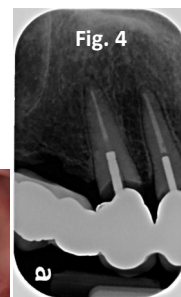
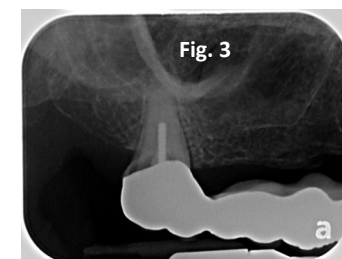
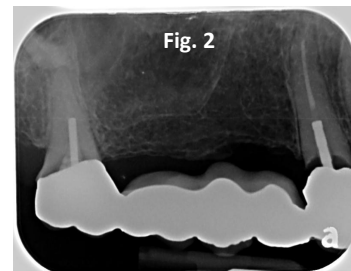
**Some people still believe that once they have crowns in their mouth, they are protected from further decay.**

**Meet Jane** A delightful lady who has undergone full mouth reconstruction at a young age due to “soft teeth”. In her mid twenties, Jane was wearing down her teeth, had rampant decay and was already missing some teeth due to early extraction. She always attended the dentist for routine care but to no avail. Jane had heavy parafunctional habits and has previously fractured porcelain on some of her earlier crowns.

*Jane is a busy lady and has let her oral health care slide. Her upper right side is in trouble.*

Fig. 1 illustrates the maxillary occlusal scheme. Jane has already fractured some of the porcelain on incisal edges. Radiographs confirm advanced dental caries in this region. (Fig. 2,3,4,5))

Jane’s reason for presentation after a long absence is due to the fractured porcelain on the upper right side and a loose upper right bridge & caries lower left side (Fig. 6,7,8)



## Why did the upper right bridge fail?

The span of the pontic area is too long. Jane did not wish to have dental implants placed in the edentulous region (or a removable partial denture) when the original bridge was fabricated 20 years ago. Even though we double abutted the anterior teeth #12,13, the edentulous span was still too long. Occlusal forces may have resulted in loosening of the bridge with subsequent caries that formed in the area.

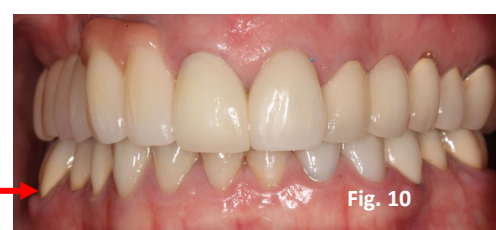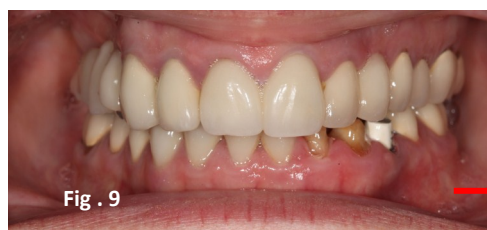## Prognosis of upper right teeth?

Abutments #17,13,12 have a hopeless prognosis and should be extracted.

Abutment #11 has advanced dental decay but can be salvaged. The buccal gingival tissues require crown lengthening for aesthetic reasons.

Our patient requests not to be edentulous at any time during her treatment.

## What are the important steps in pursuit of excellence?



## Simultaneous placement of dental implants into extraction sockets often results in loss of buccal bone around implants!

The culprit is "Bundle Bone". No matter how good a surgeon we are, there will always be loss of some of the buccal plate (Bundle Bone) following tooth extraction. To avoid loss of buccal bone, it is usually recommended that we wait 2 to 3 months after tooth extraction before the dental implants are placed ("delayed implant placement"). Whether "ridge augmentation" or "socket preservation" is completed at the time of tooth extraction, we will still lose the bundle bone. To avoid bone loss around dental implants, the following technique is suggested in fresh extraction sockets. (Fig. 11)

Dentists must avoid placing the dental implant directly into the middle of the tooth socket or they may see an end result as in Fig. 12.

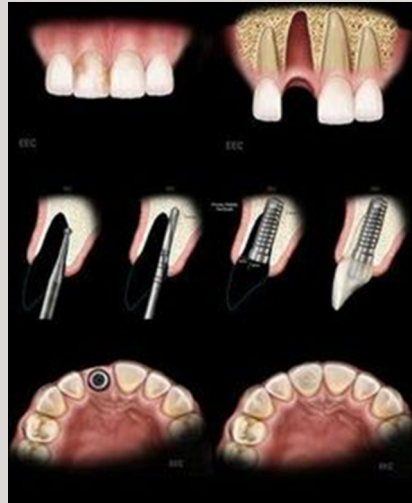


Fig. 11

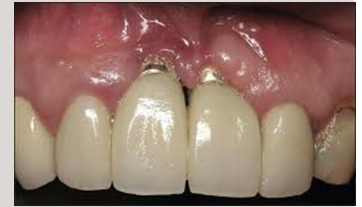

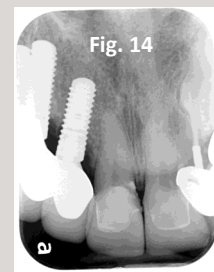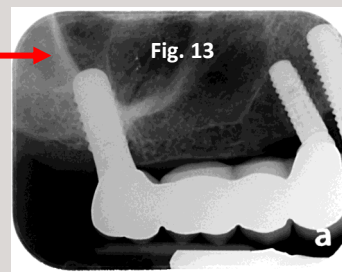
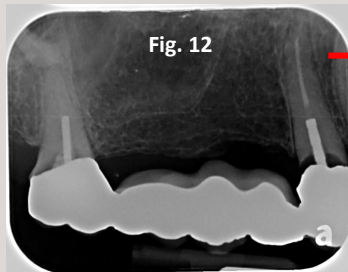
Fig. 12

Simultaneous Extraction and Implant Placement. The Technique:

- ◆ Consider flapping the buccal tissues to expose possible bone fenestrations and to aid in placement of collagen membranes
- ◆ Offset the center point of the pilot drill toward the lingual plate leave room for bone augmentation on the buccal wall both within the socket and external to the buccal plate.

### TREATMENT RESULTS:

- ◆ Placement of a fixed partial denture from #17 to #12 with pontics #16,15 and implant abutments #17,14,13,12
- ◆ Crown lengthening on #11
- ◆ Single "all ceramic" crown on #11
- ◆ Application of pink porcelain for aesthetic reasons in region of #12,13,14

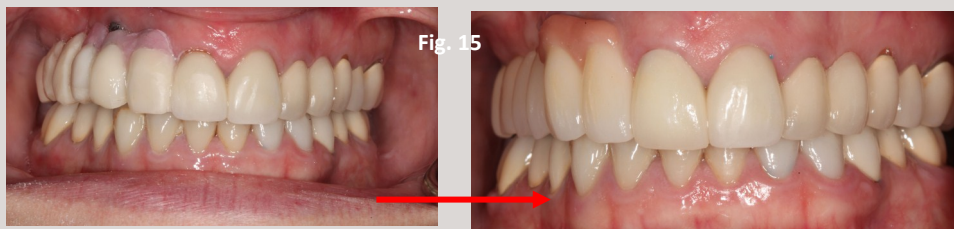

### Fixed Bridge:

Implants at: #17,14,13,12

Pontics at: #16,15

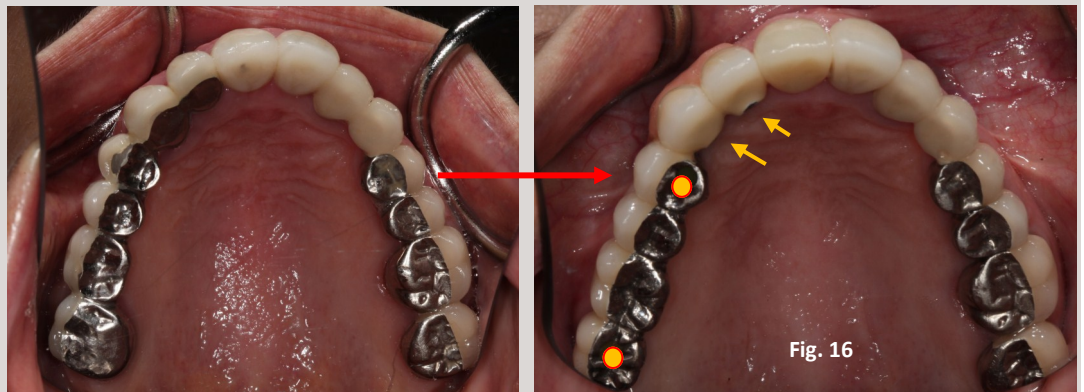Fig.12,13,14



Testing the addition of pink acrylic in the temporary bridge and adding pink porcelain in the final bridge. (Fig. 15)

### About my lab technician:

Masoud Niknejad of Picasso Dental Studios is a Master Ceramist. He maintains his own laboratory in Richmond Hill, Ontario.



### YOUR COMMENTS ARE ALWAYS WELCOME:

Since hindsight is always 20\20, different treatment plans could have been considered. Let me know what you think..... Dr. Rubinoff

- Occlusal screw access channel
- Lingual set screw access channel

Fig. 16