

November 3, 2014



Dr. Morley S. Rubinoff,
Prosthodontist
Implant Dentistry

**Suite 100, 2001 Sheppard
Avenue East
Toronto, Ontario, M2J 4Z7**

**Office: 416 499-1704
Cell: 416 838-1622
Fax: 416 751-1045**

Email:
drmorleyrubinoff@bell.net
drmorleyrubinoff@gmail.com

Fellow: International Team for
Implantology (Canada Section)



The use and abuse of Mini Implants



RE: MINI IMPLANTS:

"The mini-dental implants that Dr. X placed are not considered appropriate for long term crown fixation, yet permanent crowns were cemented on the mini-implants."

Wow! How did the RCDS of Ontario come to this conclusion? Don't they realize that mini implants are used all around the world! Yes they do and its great that they have drawn a line in the sand.

Here is a quote from a USA dentist, Dr. Joe Gillespie, who lectures globally. His topic is:

"Changing your Patient's Lives and your Practice's Bottom Line with Mini Implants".

Dr. Joe Gillespie claims to have placed over 7000 mini implants and trained over 3000 dentists in the protocol of mini implants.

Mini implants are great for provisional support of implant dentistry "under construction" or during orthodontic treatment but mini's fail frequently when used with final prosthetics.

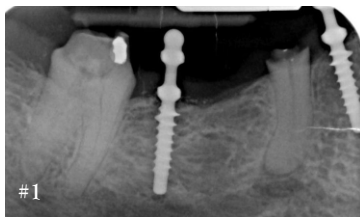
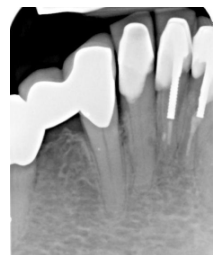
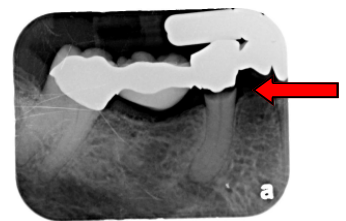
Implant failure often results from:

- Fatigue fracture of metal (implants are usually only 2.2mm in diameter or less.
- Failure to integrate as mini implants are most often made of metal alloy that will not bond to human bone
- Lack of prosthetic adaptor selection that will successfully anchor fixed or detachable prosthetics.

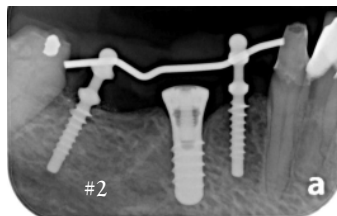
Pre-treatment radiographs illustrate advanced caries on abutment #45. Abutment #43 and #47 show no caries or bone loss around abutments.

CASE ONE:

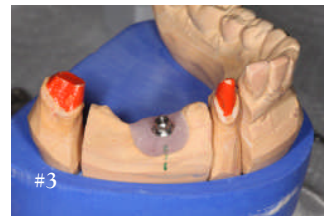Our patient is a 70 year old female that has experienced recurrent decay around a lower right fixed bridge. Treatment will be staged to first extract the failed abutment #45 and grow bone. Following healing, an implant will be placed in the #45 site and final prosthetics may proceed. Our patient wants a fixed provisional prosthesis. Mini implants are frequently used in such cases to keep our patient comfortable during the healing period.



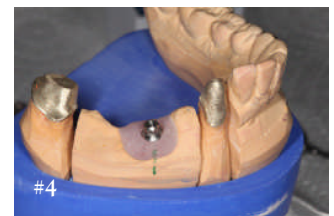
#1 Mini implants placed prior to extraction



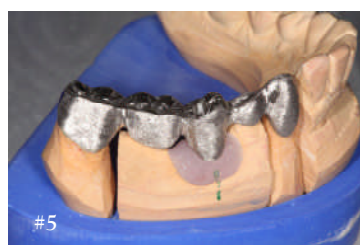#2 Minis retained as Implant heals



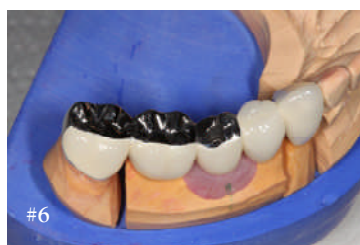#3 Minis removed for final impression



#4 Telescopic copings made for bridge



#5



#6

#5 Metal framework for bridge with implant abutment and telescopic copings in place

#6 Occlusion with three quarter metal. The telescopic copings on #47 & #43 are cemented with a resin bonded material (Multi-link by Ivoclar). The bridge is cemented with Temp Bond by Kerr and there is an occlusal access implant screw on the implant abutment #45

About my Ceramist:

Masoud Niknejad of Picasso Dental Studios is a Master Ceramist. He maintains his own laboratory in Richmond Hill, Ontario.



FUTURE BLOGS:

- ◆ The controversy of flapless implant surgery
- ◆ The problem with angulated dental implants.
- ◆ Cowboys vs "Followers"- Surgical Considerations
- ◆ Cowboys vs "Followers" - Prosthetic Considerations
- ◆ Occlusal Considerations in Restorative Dentistry
- ◆ The "hype" on fancy "gadgets" to check occlusion.
- ◆ Bikini Dentures vs functional stability in removable Prosthodontics
- ◆ And the list goes on.....

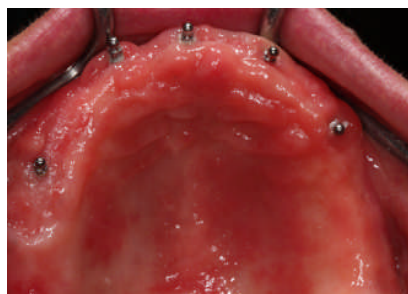
EDITOR'S NOTE:

Blogs are a great way to share information. We all know that there are many ways to complete treatment in dentistry.

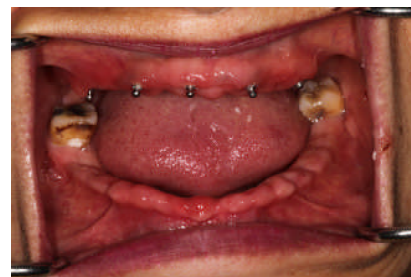Please do not hesitate to contact me if you have any questions with regards to concepts described in my blogs. Further, I am always happy to assist you with patient care concerns from your own office.

CASE TWO:

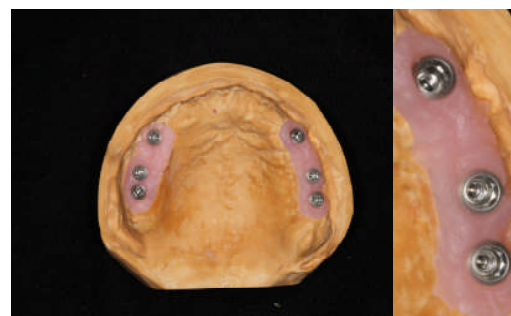Removing a full complement of teeth and inserting provisional dentures is usually very upsetting to most of our patients. Add to this insult, the time required for bilateral bone augmentation of the maxillary sinus region and we have one frustrated patient. Our patient is a 50 year old female. Following the extraction of her upper and lower teeth, temporary dental implants are inserted in the maxilla to aid in denture retention. The final reconstruction utilizes 6 Straumann tissue level implants in both the maxilla and the mandible. The prosthetics features Bredent stud snaps along fixed metal bar.



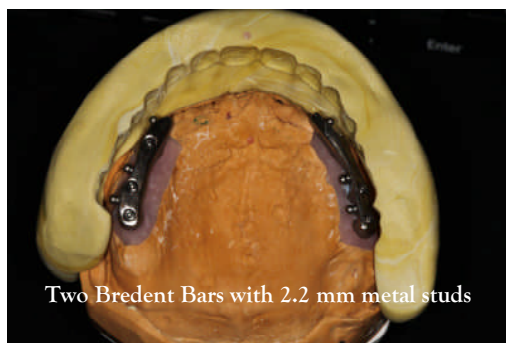
Six maxillary temporary implants are placed in the maxilla in between teeth that are to be extracted by Periodontist Dr. Michael Landzberg. The temporary implants remained in the mouth for about 12 months.



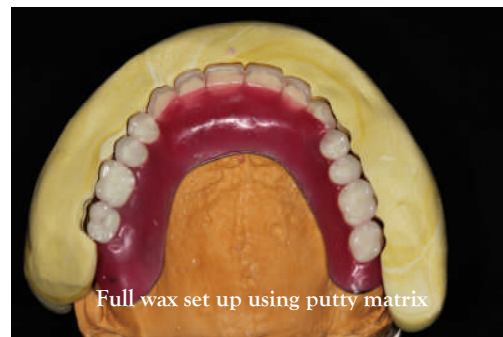
Temp Implants Straumann



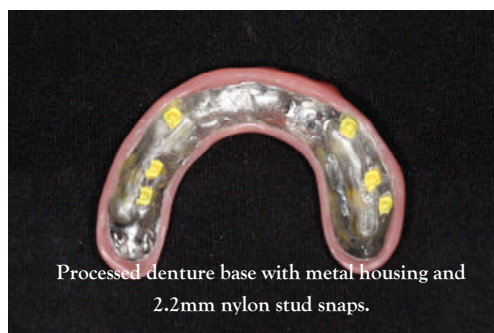Six tissue level dental implant analogues placed in the maxilla



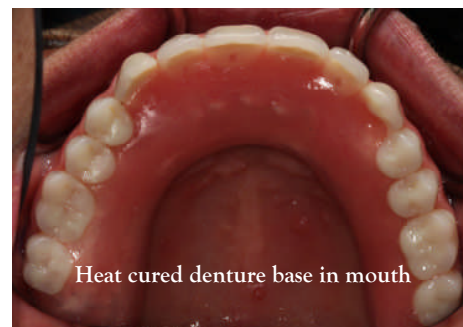Two Bredent Bars with 2.2 mm metal studs



Full wax set up using putty matrix



Processed denture base with metal housing and 2.2mm nylon stud snaps.



Heat cured denture base in mouth