

December 15, 2014



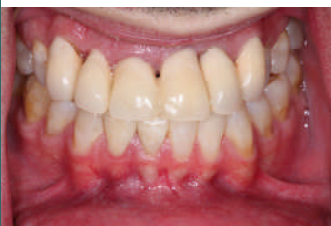Dr. Morley S. Rubinoff,
Prosthodontist
Implant Dentistry

Suite 100, 2001 Sheppard
Avenue East
Toronto, Ontario, M2J 4Z7

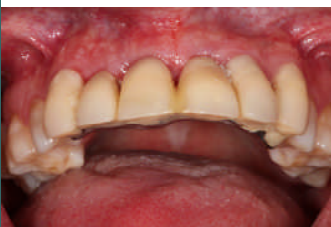Office: 416 499-1704
Cell: 416 838-1622
Fax: 416 751-1045

Email:
drmorleyrubinoff@bell.net
drmorleyrubinoff@gmail.com

Fellow: International Team for
Implantology (Canada Section)



Temporary acrylic bridge
on abutments #13, 11, 22, 23
and pontics #12, 21



Temporary acrylic bridge is reinforced with metal to prevent fracture of the prosthesis during healing.

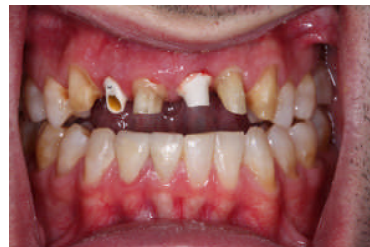Sports Injuries involving Dental Trauma:

Why should I wear a mouth guard? It's baseball, not hockey or football! Well, the ball took a lousy hop and the result was a devastating blow to this young man's mouth.

Today's blog is all about dental trauma.....fractured teeth, fractured alveolus, placement of dental implants and preservation of the all important interdental papillae. Dr. David Garber (from Atlanta, Georgia) became famous when he said "Tissue is the issue but bone sets the tone". When teeth are lost, how do we preserve the hard and soft tissue architecture as a result of multiple tooth loss?

TREATMENT CONCERNS:

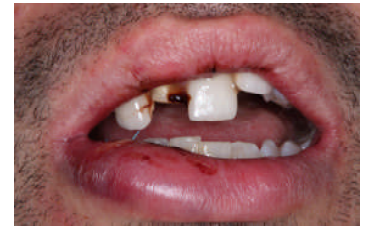The removal of all three abutments #12, 11, 21 will likely result in the immediate loss of the inter dental bone between #12, 11, 21. Subsequently, we can expect the loss of the interdental papillae and the development of "dark triangles" at the gingival crest between abutments #12, 11, 21. By retaining abutment #11 until after implant healing is complete in the region of #12, 21, it is hoped to maintain the interdental papillae in the region.



Temporary implant abutments on #12, 21 before extraction of #11.

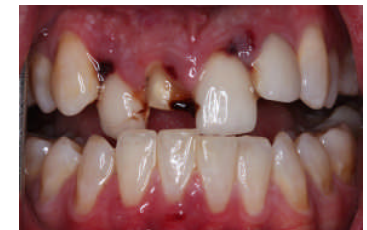CASE DESCRIPTION:

A 25 year old male takes a baseball in the mouth and fractures several upper and lower teeth.



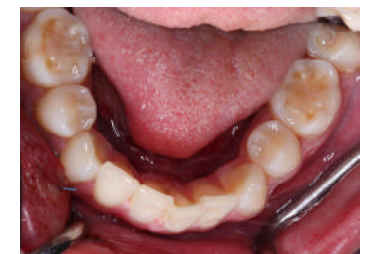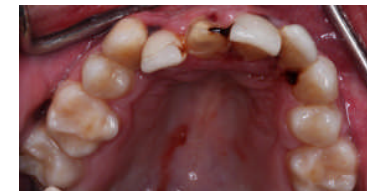Dental Injury sustained

- Partial avulsion of #12, 11, 21
- Fractured alveolus anterior maxilla
- Fractured enamel #41, 31

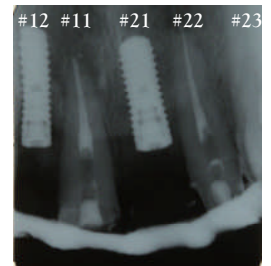


Treatment Plan:

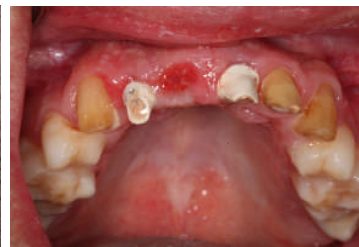- Immediate extraction #12, 21
- Immediate RCT #11, 22, 41, 42
- Provisional acrylic bridge #13-(12)-11-(21)-22-23
- After 2 months, implant placement #12, 21
- After 2 more months, temp implant bridge abutments #12, 21 & extract #11
- After 2 more months, add temp implant abutment #11 to temporary bridge
- After 1 month, finish treatment re single ceramic crowns #13, 22, 23, 41, 42



- Insertion of three porcelain bonded to metal implant retained crowns with lingual set screw retention re #12, 11, 21



Radiograph illustrates temporary retention of the natural tooth #11 until healing is complete in the region of implant abutment #12, 21. Endodontics was required due to deep sub gingival fracture on lingual of #11.



Following extraction of #11, a third dental implant has been placed in region of #11 incisor.

About my Ceramist:

Masoud Niknejad of Picasso Dental Studios is a Master Ceramist. He maintains his own laboratory in Richmond Hill, Ontario.



FUTURE BLOGS:

- ◆ Cowboys vs "Followers"- Surgical Considerations
- ◆ Cowboys vs "Followers" - Prosthetic Considerations
- ◆ Occlusal Considerations in Restorative Dentistry
- ◆ The "hype" on fancy "gadgets" to check occlusion.
- ◆ Bikini Dentures vs functional stability in removable Prosthodontics
- ◆ Training Tissues in Implant Dentistry (Emergence Profile)
- ◆ The Perils of "Thin\Scalloped" Gingiva -a Restorative Perspective

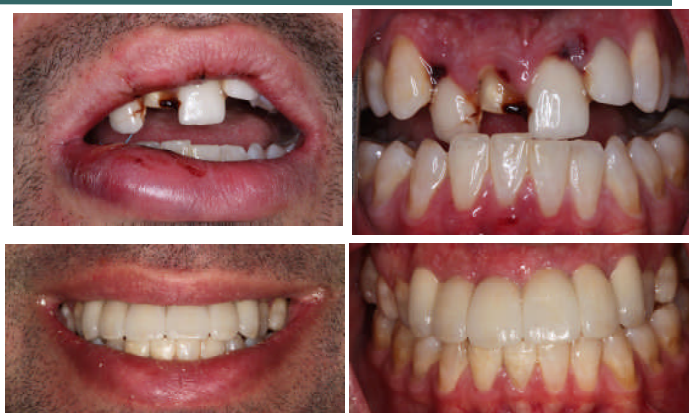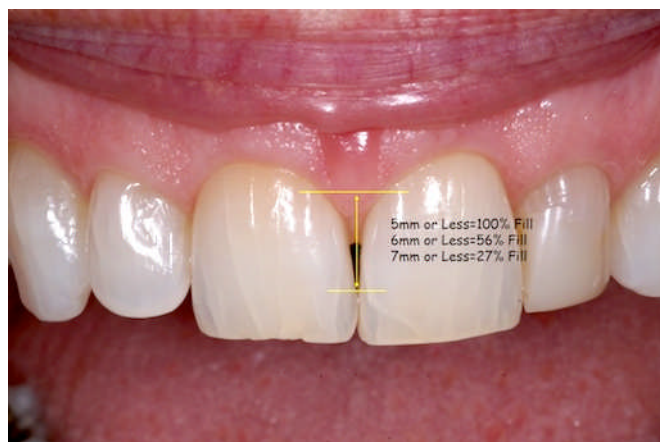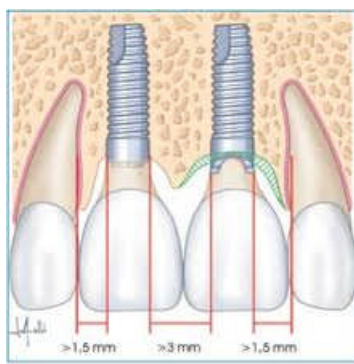
EDITOR'S NOTE:

Blogs are a great way to share information. We all know that there are many ways to complete treatment in dentistry.

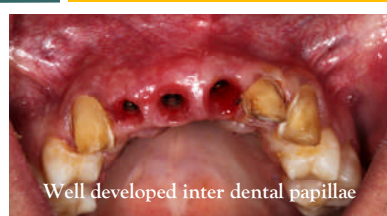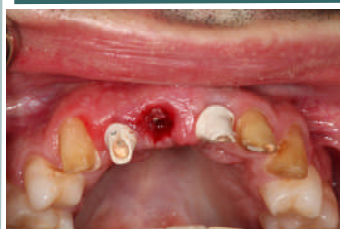Please do not hesitate to contact me if you have any questions with regards to concepts described in my blogs. Further, I am always happy to assist you with patient care concerns from your own office.

Dr. Dennis Tarnow's research on "The Effect if Inter Implant Distance on the height of Inter Implant Bone Crest" is well known.

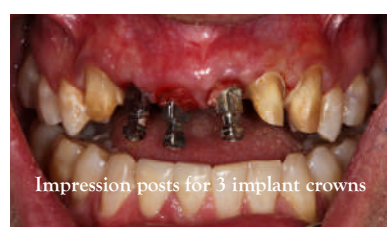
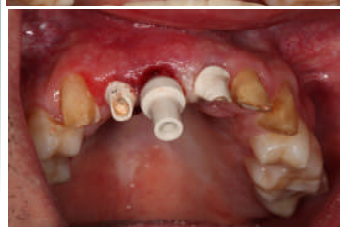
- There must be a minimum of 1.5mm of inter dental bone on each side of the implant in order to maintain the inter-dental crestal bone.
- "It is commonly observed that its more difficult to create or to maintain a papilla between two dental implants." When the distance from the contact point (of the teeth) to the crest was 5 mm (interproximal), the full papilla was almost always present.



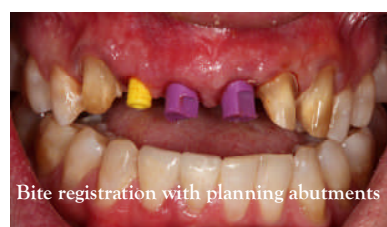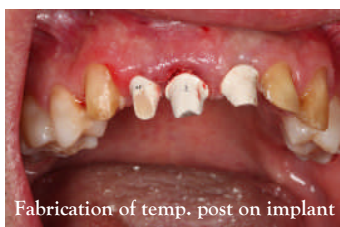
Pre and post treatment photos show the development of inter dental papillae in the maxillary anterior around dental implants.



Well developed inter dental papillae



Impression posts for 3 implant crowns



Fabrication of temp. post on implant

Bite registration with planning abutments

